

## **Case report**

# **Hypertrophic osteoarthropathy related to end stage cholestatic cirrhosis: reversal after liver transplantation**

J P HUAUX,<sup>1</sup> A GEUBEL,<sup>2</sup> B MALDAGUE,<sup>3</sup> P MICHELSEN,<sup>5</sup>  
B DE HEMPTINNE,<sup>4</sup> J B OTTE,<sup>4</sup> AND C NAGANT DE DEUXCHAISNES<sup>1</sup>

*From the <sup>1</sup>Rheumatology and <sup>2</sup>Gastro-enterology Units, Departments of Medicine, <sup>3</sup>Radiology, and <sup>4</sup>Surgery, St-Luc University Hospital, avenue Hippocrate 10, B-1200 Brussels; and the <sup>5</sup>Gastro-enterology Unit, AZ Antwerpen, Belgium*

**SUMMARY** A case is reported of hypertrophic osteoarthropathy with recovery after a liver graft in a young man with end stage cholestatic cirrhosis related to non-Wilsonian copper overload. To our knowledge this is the first case in the literature illustrating the curative role of liver grafting on hypertrophic osteoarthropathy associated with chronic cholestatic liver disease.

Hypertrophic osteoarthropathy occurs in association with various liver diseases. This extrahepatic condition was described at the end of the 19th century and thoroughly reviewed by Coury.<sup>1</sup> Hypertrophic osteoarthropathy occurs mostly in biliary cirrhosis<sup>2</sup> but was described in other liver diseases,<sup>3</sup> such as portal cirrhosis,<sup>4</sup> secondary hepatic amyloidosis,<sup>2</sup> alcoholic cirrhosis,<sup>1</sup> and biliary atresia.<sup>5</sup> We observed a case of hypertrophic osteoarthropathy in a young adult suffering from chronic cholestatic cirrhosis and had the opportunity to follow up the evolution of his osteoarticular illness after a successful liver graft.

### **Case report**

A 20 year old patient was admitted to our university hospital on 15 January 1985 for orthotopic liver transplantation because of end stage cholestatic liver cirrhosis. He was said to have had hepatomegaly since birth. A portocaval shunt for bleeding oesophageal varices was performed in 1978, and from 1983 the patient developed features of severe and progressive cholestasis. A complete liver diagnostic investigation, to be reported in detail elsewhere, established a diagnosis of micronodular cirrhosis together with massive copper overload, but without the usual features of Wilson's disease. In the

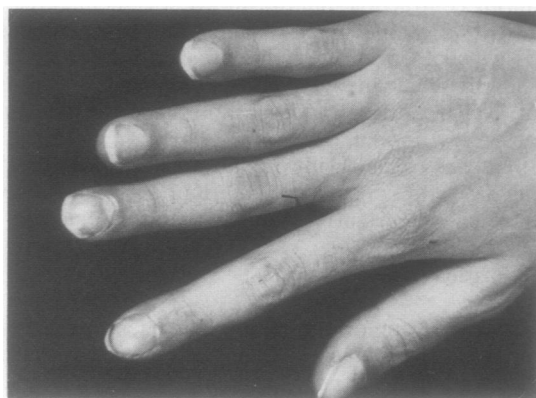

Fig. 1A

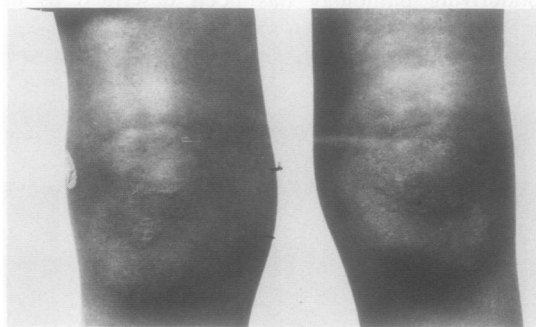
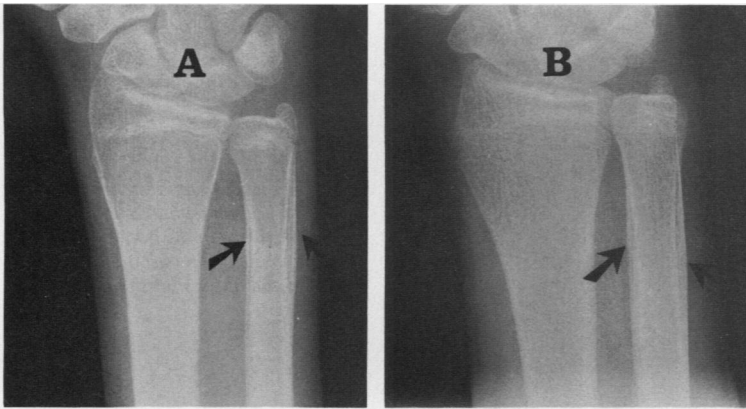


Fig. 1B

**Fig. 1** (A) Clubbing of fingers; (B) soft tissue swelling of both knee joints.

Accepted for publication 15 October 1986.

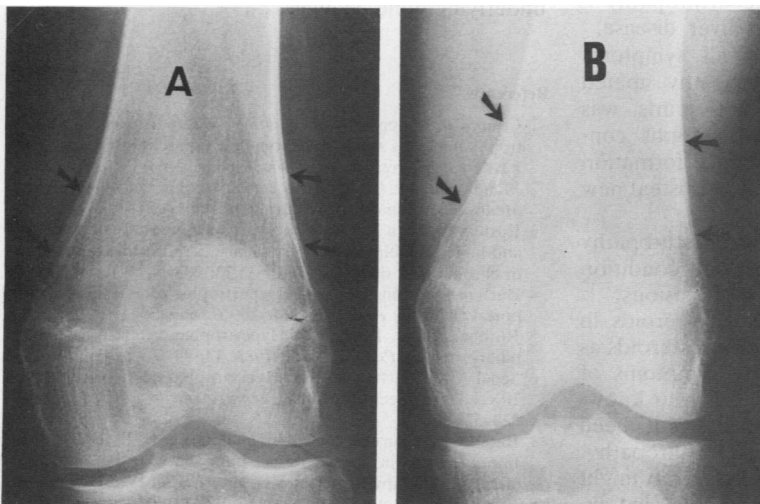
Correspondence to Dr J P Huaux, Rheumatology Unit, St-Luc University Hospital, avenue Hippocrate 10, B-1200 Brussels, Belgium.



**Fig. 2** (A) January 1985: subperiosteal new bone formation along the ulnar shaft (arrows); (B) May 1985: the periosteal apposition is being partially incorporated into the bone cortex (arrows).

six months before his admission he had developed polyarthrititis involving the wrists, ankles, and knees. When seen in our institution he complained of pain in both knees when walking and of swollen and painful wrists. On examination, clubbing of fingers was noted (Fig. 1A). There was painful thickening of forearms and distal parts of legs as well as joint effusion in both knees (Fig. 1B). Joint aspiration was performed in the right knee. The synovial fluid stained with bile showed a normal viscosity and contained a few hundred lymphocytes per micro-litre. Radiographs of wrists, knees, bones of forearms (Fig. 2A), and femur (Fig. 3A) showed diffuse and symmetrical periosteal new bone formation involving the shaft and diaphyseal regions of bones

and separated from the bony cortex by a narrow, radiolucent line. Soft tissue of the wrist overlying the distal part of the forearm bones was hypertrophied. Radionuclide bone scan with polyphosphate demonstrated linear concentration of nuclide along the bones involved and hot spots in epiphyseal areas (Fig. 4). The diagnosis of hypertrophic osteoarthropathy related to liver cirrhosis was made after all other causes of polyarthrititis had been ruled out. The patient underwent a successful liver graft in March 1985. The immunosuppressive therapy that followed included the prescription of prednisolone (10 mg/24 h) and cyclosporin (14 mg/kg/day). In May 1985 the painful swelling of the forearms had disappeared. The knees remained painful with joint



**Fig. 3** Radiograph of the right knee. (A) January 1985: periosteal new bone formation along the femoral shaft; (B) May 1985: incorporation of periosteal apposition within the femoral cortex.

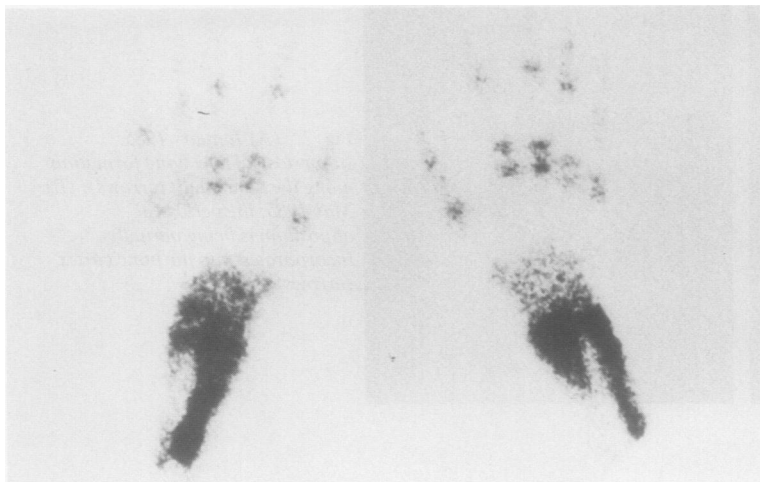


Fig. 4 Radionuclide bone scan ( $^{99m}\text{Tc}$  polyphosphate): hyperfixation of the bone seeking agent in the distal part of both radial and ulnar shafts (January 1985).

effusion still present. In June 1985 the patient was free from all symptoms related to joints and examination was normal. Radiographs showed periosteal new bone being partially incorporated into the bone cortex (Figs 2B and 3B). In March 1986 he was still in good health.

## Discussion

Our patient had the classical triad of features associated with hypertrophic osteoarthropathy, namely clubbing, periostitis, and synovitis. The joint fluid was typical of hypertrophic osteoarthropathy synovitis, with a normal viscosity and a low white cell count.<sup>6</sup> The hypertrophic osteoarthropathy is likely to have been related to his liver disease.

After the successful liver graft all symptoms related to hypertrophic osteoarthropathy abated quickly. Complete recovery of the joints was achieved a few months later. Radiographs confirmed the arrest of periosteal new bone formation and the progressive incorporation of periosteal new bone into the adjacent cortex.

The reversal of hypertrophic osteoarthropathy with the ablation or cure of the underlying condition has been well demonstrated on several occasions.<sup>7-12</sup> The influence of adrenocortical corticosteroids in our patient cannot be ruled out. Indeed, steroids as well as salicylates can improve the symptoms of hypertrophic osteoarthropathy.<sup>6 13 14</sup> To our knowledge the efficacy of cyclosporin has not been demonstrated in hypertrophic osteoarthropathy. Conceivably, prednisolone and the liver graft might act in different ways, the former suppressing in-

flammation in a non-specific manner, and the latter arresting the evolution of the osteoarticular disease by removing the main pathogenetic factor.

Whatever the main cause of resolution in our patient it can be concluded that the hypertrophic osteoarthropathy related to cholestatic cirrhosis runs a course similar to that of other causes, mainly pulmonary or infectious. Indeed, as soon as the underlying cause is corrected and active drugs administered the condition disappears within a few months. Until recently there was no effective therapy for end stage liver cirrhosis. The improving results and the growing application of liver transplantation now allow relief of the clinical features of hypertrophic osteoarthropathy and reversal of the underlying bone changes.

## References

- 1 Coury Ch. L'hypocratismes digital. L'ostéo-arthropathie hypertrophique et les autres dysacromélies apparentées. In: Baillière J B, ed. *Les prédis du praticien*. 1960; 112-63.
- 2 Mendlowitz M. Clubbing and hypertrophic osteoarthropathy. *Medicine (Baltimore)* 1942; 21: 269-306.
- 3 Epstein O, Dick R, Sherlock S. Prospective study of periostitis and finger clubbing in primary biliary cirrhosis and other forms of chronic liver disease. *Gut* 1981; 22: 203-6.
- 4 Buchan D J, Mitchell D M. Hypertrophic osteoarthropathy in portal cirrhosis. *Ann Intern Med* 1967; 66: 130-5.
- 5 Rothberg A D, Boal D K. Hypertrophic osteoarthropathy in biliary atresia. *Pediatr Radiol* 1983; 13: 44-6.
- 6 Segal A M, Mackenzie A H. Hypertrophic osteoarthropathy: a 10-year retrospective analysis. *Semin Arthritis Rheum* 1982; 12: 220-32.
- 7 Rao G M, Gurupoakash G H, Poulse K P, Bhaskar G. Improvement in hypertrophic pulmonary osteoarthropathy after radiotherapy to metastasis. *Am J Radiol* 1979; 133: 944-6.
- 8 Evans W K. Reversal of hypertrophic osteoarthropathy after

- chemotherapy for bronchogenic carcinoma. *J Rheumatol* 1980; **7**: 93–7.
- 9 Vasudevan C P, Suppiah P, Udoshi M B, Lusins J. Reversible autonomic neuropathy and hypertrophic osteoarthropathy in a patient with bronchogenic carcinoma. *Chest* 1981; **79**: 479–81.
- 10 Lester W M, Robertson D I. Hypertrophic osteoarthropathy complicating metastatic ovarian adenocarcinoma. *Can J Surg* 1981; **24**: 520–3.
- 11 Barber P V, Lechler R. Hypertrophic osteoarthropathy: two unusual causes. *Postgrad Med J* 1983; **59**: 254–5.
- 12 Donckier J, Minette Ph, Trigaux J P, Vanderstappen M, Delaunois L, Buysschaert M. Réversibilité d'un syndrome de Pierre-Marie. A propos d'une observation. *Louvain Med* 1985; **104**: 313–6.
- 13 Schumacher H R. Articular manifestations of hypertrophic pulmonary osteoarthropathy in bronchogenic carcinoma. A clinical and pathologic study. *Arthritis Rheum* 1976; **19**: 629–36.
- 14 Petty R E, Cassidy J T, Heyn R, Kenien A G, Washburn R L. Secondary hypertrophic osteoarthropathy. An unusual cause of arthritis in childhood. *Arthritis Rheum* 1976; **19**: 902–6.