



Charcot-Bouchard Aneurysm Diagnosed with CTA and MRA

CASE REPORT

SANAA JAMALI

JOSÉ GÉRALDO RIBEIRO VAZ

GUIDO WILMS

**Author affiliations can be found in the back matter of this article*

]u[ubiquity press

ABSTRACT

Hemorrhage in the basal ganglia resulting to lenticulostriate artery aneurysm rupture is extremely rare. This distal micro-aneurysm of the perforating lenticulostriate arteries is called Charcot-Bouchard aneurysm. We wish to report a case of an hematoma in the basal ganglia due to a Charcot-Bouchard aneurysm demonstrated by Computed Tomography Angiography (CTA) and Magnetic Resonance Angiography (MRA) and confirmed by selective catheter angiography.

Teaching Point: Charcot-Bouchard aneurysm is a very rare distal micro-aneurysm of the perforating lenticulostriate arteries. Young patients who experience basal ganglia hemorrhage should have contrast-enhanced CT, especially if they don't have arterial hypertension and if subarachnoid hemorrhage is associated.

CORRESPONDING AUTHOR:

Sanaa Jamali

Clinique Saint Luc, BE

jmsanaa@gmail.com

KEYWORDS:

Charcot-Bouchard aneurysm;
basal ganglia hematoma

TO CITE THIS ARTICLE:

Jamali S, Vaz JGR, Wilms G.
Charcot-Bouchard Aneurysm
Diagnosed with CTA and MRA.
*Journal of the Belgian Society
of Radiology*. 2021; 105(1):
13, 1–3. DOI: [https://doi.
org/10.5334/jbsr.1934](https://doi.org/10.5334/jbsr.1934)

CASE REPORT

A 47-year-old male patient with a known history of arterial hypertension and migraine suffered a sudden right facio-brachial paresis and dysarthria. National Institutes of Health Stroke Scale (NIHSS) score was 6. Emergency computed tomography (CT) showed a recent hemorrhage in the left basal ganglia (**Figure 1a**) with some subarachnoid hemorrhage in the left insula and the cistern of the middle cerebral artery (**Figure 1b**). CT angiography (CTA), performed because of the young age of the patient and the presence of subarachnoid blood, showed a small distal lenticulostriate aneurysm (**Figures 1c** and **1d**). This was confirmed a few days later by magnetic resonance angiography (MRA) (**Figure 2**) and finally by selective left carotid angiography (**Figure 3**). Because of the distal location of the aneurysm it was decided to remain conservative. During the following weeks there was good recuperation of the clinical symptoms with a persistent slight facial asymmetry. Patient is followed up yearly by MRA.

DISCUSSION

Basal ganglia hemorrhages in patients with chronic arterial hypertension are frequent. In this context, intravenous contrast is not routinely administered for CT. In our patient, the simultaneous presence of subarachnoid blood

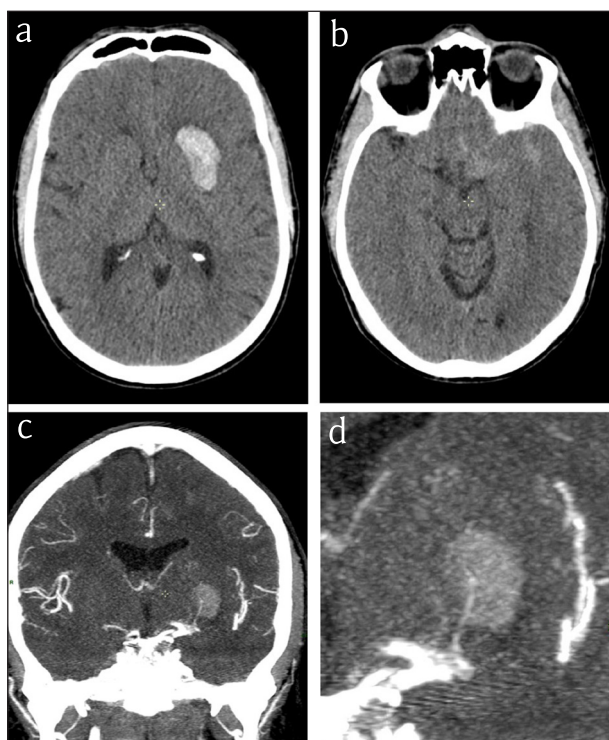


Figure 1 CT. (a) Plain CT: Hemorrhage in the left basal ganglia (Arrow) (b) Plain CT at a lower level: Notice subarachnoid hemorrhage in the cistern of the middle cerebral artery and the insula (arrowheads) (c) CTA: Notice fusiform aneurysm (arrow) on a distal lenticulostriate artery. (d) Magnified view of CTA showing the aneurysm in continuity with the lenticulostriate artery (arrow).

in the insular cistern and his young age triggered CTA, which allowed us to detect the small Charcot-Bouchard aneurysm. To date, only approximately 60 cases of Charcot-Bouchard aneurysms are reported. They mostly

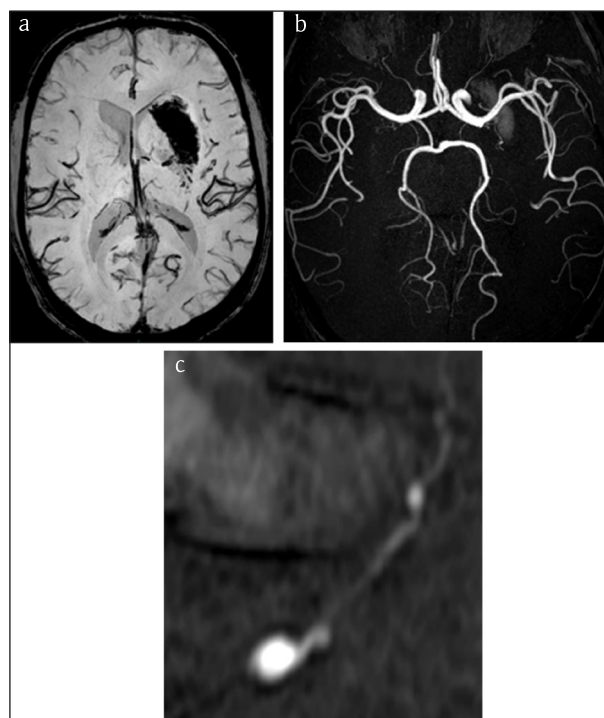


Figure 2 MRI. (a) SWI sequence of MRI: Susceptibility artifacts in the left lentiform nucleus due to hemorrhage. (b) MRA with TOF sequence: Notice aneurysm as a dense spot (arrow) in the T1 hyperintense hemorrhage. (c) MIP of MRA with reconstruction: Notice fusiform dilatation of distal lenticulostriate artery (arrow).

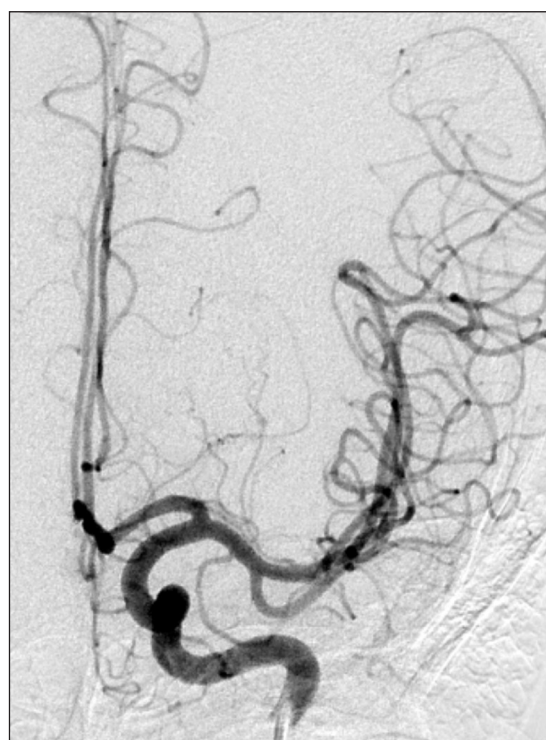


Figure 3 Selective catheter angiography: Fusiform Charcot-Bouchard aneurysm on distal lenticulostriate artery (arrow).

present at a younger age with a mean of 41.9 years [1], and not all patients are hypertensive. The primary type of distal lenticulostriate aneurysms is probably dissecting or pseudo-aneurysms, but true saccular aneurysms exist [1]. They mostly lead to solitary hematomas in the basal ganglia mimicking hypertensive hemorrhage [2]. The hematoma in the basal ganglia may be accompanied by subarachnoid hemorrhage as in our case.

Diagnosis of Charcot-Bouchard aneurysms now can be based on CTA showing an enhancing spot in the hematoma. This so-called spot sign is important to recognize, as it indicates active bleeding and predicts rapid hematoma expansion. The lesion can also be shown on MRA [1] or contrast-enhanced T1-weighted MR. In some cases, however, cross-sectional imaging may fail to display the lesion, which makes catheter angiography the diagnostic standard of reference [1].

Treatment of Charcot aneurysms would be indicated if the aneurysm is saccular or exceeds 5 mm [1]. Treatment options include surgery or embolisation. Conservative management can be considered if the aneurysm is small and fusiform as in our case. The aneurysm will progressively disappear on follow-up imaging in the following years.


To conclude, as there is no difference on non-contrast CT between Charcot aneurysm and hemorrhage without

aneurysm, we recommend to carefully perform CTA when the patient is young, when subarachnoid blood is present and/or when there is no context of arterial hypertension.

COMPETING INTERESTS

The authors have no competing interests to declare.

AUTHOR AFFILIATIONS

Sanaa Jamali  orcid.org/0000-0001-9322-1256
Cliniques Universitaires Saint Luc, BE

José Geraldo Ribeiro Vaz  orcid.org/0000-0002-5132-932X
Cliniques Universitaires Saint Luc, BE

Guido Wilms  orcid.org/0000-0003-1184-8309
Cliniques Universitaires Saint Luc, BE

REFERENCE

1. **Nomura M, Baba E, Shirokane K, Tsuchiya A.** Aneurysm of lenticulostriate artery in a patient presenting with hemorrhage in the caudate nucleus and lateral ventricle-delayed appearance and spontaneous resolution. *Surg Neurol Int.* 2018; 21(9): 192. Epub Sept 2018. DOI: https://doi.org/10.4103/sni.sni_126_18

TO CITE THIS ARTICLE:

Jamali S, Vaz JGR, Wilms G. Charcot-Bouchard Aneurysm Diagnosed with CTA and MRA. *Journal of the Belgian Society of Radiology.* 2021; 105(1): 13, 1–3. DOI: <https://doi.org/10.5334/jbsr.1934>

Submitted: 02 September 2019 Accepted: 05 January 2020 Published: 12 March 2021

COPYRIGHT:

© 2021 The Author(s). This is an open-access article distributed under the terms of the Creative Commons Attribution 4.0 International License (CC-BY 4.0), which permits unrestricted use, distribution, and reproduction in any medium, provided the original author and source are credited. See <http://creativecommons.org/licenses/by/4.0/>.

Journal of the Belgian Society of Radiology is a peer-reviewed open access journal published by Ubiquity Press.