

CASE REPORT

WILEY

Breast implant seroma: A SARS-CoV-2 mRNA vaccine side effect

Françoise Kayser MD¹  | Hadrien Fourneau MD¹  |
Olivier C. Mazy MSc Student²  | Stéphane Mazy MD³ 

¹Université catholique de Louvain, CHU UCL Namur, Department of Radiology, Avenue G Thérèse 1, 5530, Yvoir, Belgium

²Department of Pharmacy, Faculty of Medicine, Université de Namur (UNamur), Namur, Belgium

³Université catholique de Louvain, CHU UCL Namur, Department of Radiology, Place L Godin 15, 5000, Namur, Belgium

Correspondence

Françoise Kayser, Department of Radiology, Université Catholique de Louvain, CHU UCL Namur, Avenue Docteur G. Thérèse 1, B 5530 Yvoir, Belgium.
Email: francoise.kayser@uclouvain.be

Abstract

Fluid collection surrounding breast implants, called seroma, is a frequent issue that has diverse etiologies. We describe a 48-year-old woman with an acute onset of bilateral breast swelling occurring 5 years after aesthetic surgery and 10 days after a second SARS-CoV-2 mRNA vaccine dose. At breast ultrasound, we found an abundant bilateral peri-implant seroma. Our patient noticed symptom improvement 48 h after nonsteroidal anti-inflammatory drug treatment, complete disappearance of symptoms after 10 days with seroma disappearance documented by ultrasound. We hypothesized a breast implant seroma as post-SARS-CoV-2 mRNA vaccine side effect, as different other diagnosis had been excluded.

KEYWORDS

breast implants, COVID, seroma, ultrasound, vaccine

1 | INTRODUCTION

Since a novel coronavirus was identified in December 2019 in Wuhan, China, causing a worldwide pandemic, several pharmaceutical laboratories have developed different types of COVID-19 vaccines. Coronavirus disease (COVID-19) is caused by Severe Acute Respiratory Syndrome coronavirus 2 (SARS-CoV-2). Although several local and systemic side effects as tenderness, redness, and swelling at the injection site, swollen lymph nodes in the armpit or neck, fatigue, headache, chills, fever, feeling unwell, myalgia, arthralgia, nausea, vomiting, anaphylaxis, or unexplained death^{1–4} have been related to COVID-19 vaccine, a side effect related to breast implants have not yet been described until today.

2 | CASE REPORT

A 48-year-old female patient presented to our mammography unit with a history of acute bilateral breast swelling that appeared 3 days

earlier, associated with breast pain and increased skin heat. No skin redness or fever was related. She had an unremarkable full breast workup 2 months earlier. The patient has got textured silicone gel breast implant surgery 5 years earlier for aesthetic reasons. She notified having her second SARS-CoV-2 mRNA vaccine dose (Pfizer-BioNTech) 2 weeks prior to the breast symptoms. Either after the first or the second COVID-19 vaccine dose she presented several side effects such as headache, body aches, fever at 38°C, polyarthralgia, epigastric pain, sickness, and loss of consciousness. No skin rash was notified. The breast pain and swelling appeared 10 days after the second COVID-19 vaccine dose. Clinical breast examination revealed enlarged, firm breasts without skin abnormalities. We performed bilateral breast and axillar ultrasound (US) using a RS85 Ultrasound system with a LA4-18B Hz linear-array transducer (Samsung Medison Co., Ltd, Seoul Korea) showing a diffuse fluid collection surrounding the breast implants, predominant in the right breast (Figure 1). No abnormal findings were reported in the breast tissue. The breast implants showed no signs of rupture. Enlarged lymph nodes were found in the left axilla probably related to the recent COVID-19 vaccine in the left arm. A fine needle aspiration (FNA) under US guidance with partial emptying of the seroma was performed on the right side. The cytology reported a mixed but

Abbreviations: ALCL, anaplastic large cell lymphoma; FNA, fine needle aspiration; NSAID, nonsteroidal anti-inflammatory drug; US, ultrasound.

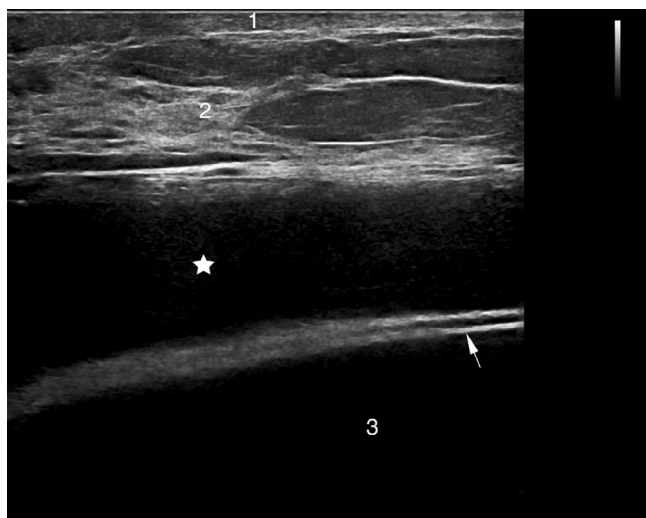


FIGURE 1 Initial ultrasound findings, in a transverse scanning plane: The initial ultrasound revealed a diffuse fluid collection surrounding the right breast implant. Skin (1), Breast tissue (2), Breast implant (3), Implant shell (arrow), Fluid collection (asterisk)

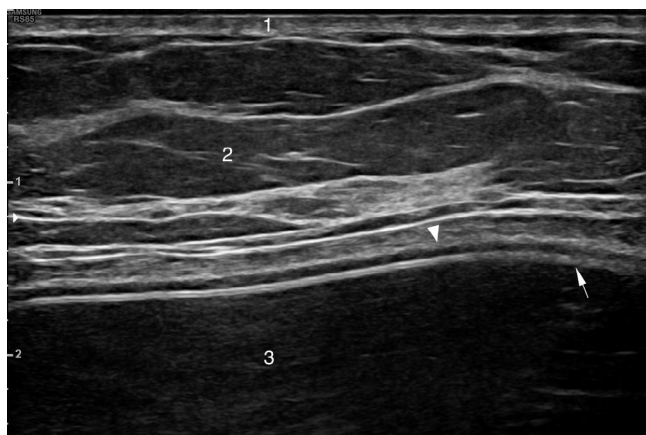


FIGURE 2 Ultrasound findings, in a transverse scanning plane, after nonsteroidal anti-inflammatory drug (NSAID) treatment: Ultrasound revealed complete disappearance of the fluid collection previously documented. Skin (1), Breast tissue (2), Breast implant (3), Implant shell (arrow), Implant capsule (arrowhead)

predominantly acute inflammation, showing rare macrophages, and numerous polynuclear neutrophils. The laboratory test results revealed elevated C-reactive protein (6.3 mg/L) without significant leukocytosis as from the first vaccine dose, lasting after the second vaccine dose. Following the second vaccine dose, several antibodies for rheumatoid disease were tested: AntiENA and AntiSSA were positive, AntiDNA negative. The patient presented no side effects to prior vaccines but related grass pollen, nut, apple, shellfish, tannin, dust mite, and wasp allergy.

The patient noticed symptom improvement 48 h after treatment by a nonsteroidal anti-inflammatory drug (NSAID), 3 × 400 mg/day, and complete disappearance of the breast pain and swelling 10 days

after. Complete disappearance of seroma was documented by US (Figure 2).

3 | DISCUSSION

Breast implant associated anaplastic large cell lymphoma⁵(ALCL) must be suspected in late-onset peri-implant breast seromas. ALCL classically appears 7–10 years after placement of a breast implant. Generally they occur as a unilateral breast enlargement with abundant effusions on US and without inflammatory signs. A FNA of the surrounding seroma is mandatory and should be submitted for cytological examination to exclude malignancy and for microbiological analysis to exclude infections; molecular analyses such as CD-30 immunohistochemistry will exclude or confirm ALCL.⁶ In our case the immunohistochemistry for CDX20, CD3, and CD30 were negative. Hence, the diagnosis of ALCL was rejected. The bacteriological analysis of the nonpurulent fluid yielded no pathogen. Moreover, no local sign of mastitis (i.e., skin redness, skin heat, tenderness) or fever was observed. Because the implant was ultrasonographically intact, a possible diagnosis of intracapsular implant rupture was ruled out.

A peri-implant hematoma was also excluded by the macroscopic aspect (i.e., color and viscosity) of the aspirated seroma and the cytological analysis. Late peri-implant hematomas are very rare and present rather as a gradual than a sudden volume increase. They may result from capsular vessel erosion due to trauma, inflammation, friction of implant against the capsule, or capsular contracture.^{7–9} Capsular contracture is the most common complication following breast implant surgery and may be responsible for a late seroma. The role of the immune system in the pathogenesis of capsular contracture has been raised.¹⁰ The diagnosis of typical capsular contracture was excluded because of the absence of the typical sonographic signs (i.e., implant deformation, increased number of radial folds, and fibrous capsule thickening¹¹), the disappearance of the bilateral seroma after NSAID treatment and the unremarkable prior full breast workup. Since we excluded the aforementioned diseases, the possibility of a breast implant seroma as post-COVID-19 vaccine side effect was retained. FDA data from the Moderna COVID-19 vaccine trial revealed facial or lip swelling related to dermal filler in three out of 15 184 SARS-CoV-2 mRNA vaccinated patients. They propose a local inflammatory reaction related to an interaction between the dermal filler and the postvaccination immune response.¹² A similar reaction was observed after influenza vaccine in the past in one of these patients. Delayed dermal filler inflammatory events occur very rarely with both hyaluronic and nonhyaluronic acid fillers.¹³ These reactions may be triggered immunologically by viral and bacterial illness, vaccinations, and dental procedures, and might be explained by a systemic immune activation triggering a systemic inflammatory response. Therefore a similar side effects on silicone implants may be expected. A local inflammation rather than an allergic mechanism as pathophysiology is suggested.¹² Eventually a serum sickness or serum sickness-like reaction^{14,15} may be suggested due to the concomitant late-onset symptoms like fever, malaise, lymphadenopathy, polyarthralgia, and gastrointestinal symptoms¹⁶ encountered in our

patient, especially since vaccines may cause serum sickness or serum sickness-like reactions.^{17,18}

In conclusion, in case of breast implant seroma, the differential diagnosis may be established by US, FNA, CD-30 immunohistochemistry, and bacteriological analysis. Treatment might include NSAID or corticoids.

CONFLICT OF INTEREST

The authors declare no potential conflict of interest.

DATA AVAILABILITY STATEMENT

Data available on request due to privacy/ethical restrictions.

ORCID

Françoise Kayser  <https://orcid.org/0000-0002-2151-9253>

Hadrien Fourneau  <https://orcid.org/0000-0002-7383-1206>

Olivier C. Mazy  <https://orcid.org/0000-0002-9976-8495>

Stéphane Mazy  <https://orcid.org/0000-0002-1389-861X>

REFERENCES

- Shmerling RH. COVID-19 vaccines: safety, side effects and coincidence. *Harvard Health Publishing, Harvard Medical School*. February 28, 2021. Accessed March 22, 2021. www.health.harvard.edu
- COVID-19 vaccines: get the facts. *Mayo Clinic*. Accessed March 22, 2021. www.mayoclinic.org
- Possible side effects after getting a COVID-19 vaccine. *Centers for Disease Control and Prevention*. March 16, 2021. Accessed March 22, 2021. www.cdc.gov
- U.S. Food & Drug Administration. Pfizer-BioNTech COVID-19 Vaccine. March 2, 2021. Accessed March 22, 2021. www.fda.gov
- Laurent C, Haioun C, Brousset P, Gaulard P. New insights into breast implant-associated anaplastic large cell lymphoma. *Curr Opin Oncol*. 2018;30(5):292-300.
- Di Napoli A. Achieving reliable diagnosis in late breast implant seromas: from reactive to anaplastic large cell lymphoma. *Plast Reconstr Surg*. 2019;143(3S a review of breast implant-associated anaplastic large cell lymphoma):15S-22S.
- Brickman M, Parsa NN, Parsa FD. Late hematoma after breast implantation. *Aesthetic Plast Surg*. 2004;28(2):80-82.
- Hsiao HT, Tung KY, Lin CS. Late hematoma after aesthetic breast augmentation with saline-filled, textured silicone prosthesis. *Aesthetic Plast Surg*. 2002;26(5):368-371.
- Kim L, Castel N, Parsa FD. Case of late hematoma after breast augmentation. *Arch Plast Surg*. 2018;45(2):177-179.
- Wolfram D, Rainer C, Niederegger H, Piza H, Wick G. Cellular and molecular composition of fibrous capsules formed around silicone breast implants with special focus on local immune reactions. *J Autoimmun*. 2004;23(1):81-91.
- Gossner J. Sonography in capsular contracture after breast augmentation: value of established criteria, new techniques and directions for research. *J Ultrasound*. 2017;20(1):87-89.
- U.S. Food and Drug Administration. Vaccines and Related Biological Products Advisory Committee Meeting; FDA Briefing Document for Moderna COVID 19 Vaccine. December 17, 2020. Accessed March 22, 2021. <https://www.fda.gov/media/144434/download>
- Avram M, Bertucci V, Cox SE, et al. Guidance regarding SARS-CoV-2 mRNA vaccine side effects in dermal filler patients. *American Society for Dermatologic Surgery*. December 28, 2020. Accessed March 22, 2021. <https://www.asds.net/Portals/0/PDF/secure/ASDS-SARS-CoV-2-Vaccine-Guidance.pdf>
- Wener MH, Adkinson NF, Jr, Feldweg AM. Serum sickness and serum sickness-like reactions. *UpToDate website*. February 5, 2021. Accessed March 22, 2021. <https://www.uptodate.com>
- Quirt J, Rogala B, Cichocka-Jarosz E. Serum sickness. *McMaster Textbook of Internal Medicine*. Kraków: Medycyna Praktyczna. March 3, 2016. Reviewed: May 28, 2019. <https://empendium.com/mcmtextbook/chapter/B31.II.17.2>
- Yorulmaz A, Akin F, Sert A, et al. Demographic and clinical characteristics of patients with serum sickness-like reaction. *Clin Rheumatol*. 2018;37(5):1389-1394.
- Bonds RS, Kelly BC. Severe serum sickness after H1N1 influenza vaccination. *Am J Med Sci*. 2013;345(5):412-413.
- Warrington RJ, Martens CJ, Rubin M, et al. Immunologic studies in subjects with a serum sickness-like illness after immunization with human diploid cell rabies vaccine. *J Allergy Clin Immunol*. 1987;79(4):605-610.

How to cite this article: Kayser F, Fourneau H, Mazy OC, Mazy S. Breast implant seroma: A SARS-CoV-2 mRNA vaccine side effect. *J Clin Ultrasound*. 2021;1-3. doi: 10.1002/jcu.23056