

# Dermatomyositis with anti-TIF1- $\gamma$ antibodies

Axel De Greef,<sup>1</sup> Liliane Marot,<sup>1</sup> Halil Yildiz,<sup>2</sup> Marie Baeck<sup>1</sup>

<sup>1</sup>Dermatology, Cliniques universitaires Saint-Luc, Bruxelles, Belgium

<sup>2</sup>Médecine Interne, Cliniques Universitaires Saint-Luc, Bruxelles, Belgium

## Correspondence to

Dr Halil Yildiz,  
halil.yildiz@uclouvain.be

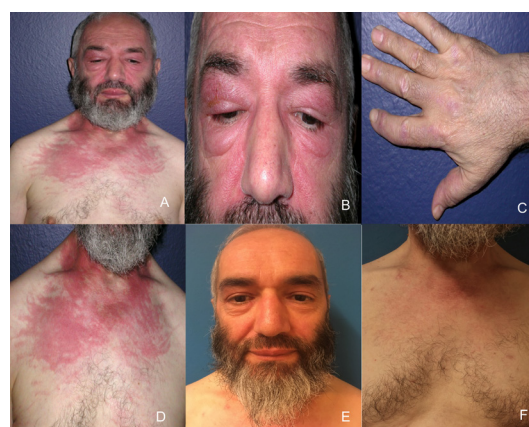Accepted 16 September 2018

## DESCRIPTION

We report the case of a 61-year-old Turkish male patient who presented to our dermatology outpatient clinic with a 1-year history of swelling and pruritic erythema rash of the face and trunk. He reported associated myalgia and arthralgia of the knees and wrists. Two months before presentation, he developed muscle weakness of upper limbs and dyspnoea. On review, he was noted to have unintentional weight loss (5 kg over 2 months) and increasing fatigue. His medical and family histories were unremarkable. His medications included omeprazole daily and vitamin B<sub>12</sub> injections. Prior to presentation to our clinic, his general practitioner treated the patient with antihistamines, topical steroids (Elocom) and a short course of oral corticosteroid therapy which only provided temporary relief. Laboratory data demonstrated C reactive protein 6 mg/L (normal value (NV) <5 mg/L), haemoglobin 11.9 g/dL (NV 13–18 g/dL), lactate dehydrogenase 467 U/L (NV 135–225 U/L), creatinine phosphokinase 295 U/L (NV 30–190 U/L), Aspartate transaminase (GOT) 75 U/L (NV 8–31 U/L), Glutamate pyruvate transaminase (GPT) 66 U/L (NV 5–31 U/L); white blood count, ionogram, lipid profile, renal function, thyroid function, haemostasis and coagulation were all normal. Hepatitis B and C, and HIV serologies were all negative. Antinuclear antibodies were positive at 1/320. Serum protein immunoelectrophoresis showed a polyclonal raise of IgG up to 21.0 g/L (normal range at 7–15 g/L).

On review of vital signs, the patient was afebrile with a heart rate 86 bpm, blood pressure of 197/95 mm Hg, normal respiratory rate and an oxygen saturation of 98% on room air. On physical examination, the patient was noted to have a bilateral heliotrope oedema including upper and lower eyelids with erythematous plaques. Additionally, he was also noted to have pronounced neck swelling (collar of Stokes), diffuse rash on upper chest and back (shawl sign), discrete red papules over finger joints of both hands (Gottron's papules) as well as over elbows and knees, and a mild periungual erythema (figure 1A–D). Periungual dermoscopic examination was unrevealing. Lungs and heart sounds were normal. Abdominal and lymph node examination were also normal.

Given the constellation of symptoms, dermatomyositis (DM) was highly suspected, and the patient was hospitalised for further investigations. The results of a skin biopsy (figure 2A,B) and electromyography were both in keeping with the diagnosis of DM. Screening for specific antibodies of DM were positive for anti-transcription intermediary factor 1 gamma (anti-TIF1- $\gamma$ ). In light of confirmed DM, we realised a paraneoplastic assessment:

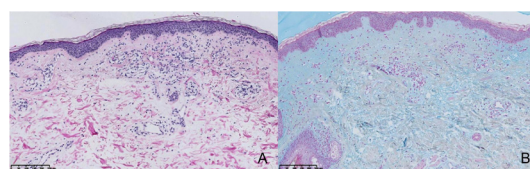


**Figure 1** (A) General aspect. Note the collar of Stokes. (B) Bilateral periorbital heliotrope erythema. (C) Erythematous papules over interphalangeal joints (Gottron's papules) and mild periungual erythema. (D) Maculopapular exanthema on patient's chest (shawl sign). (E-F). Follow-up 5 months after treatment.

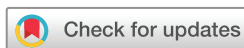Fluorodeoxyglucose positive emission tomography (<sup>18</sup>F-FDG-PET) scan, gastrocolonoscopy and thoracoabdominal CT scan were all negative, as well as carcinoembryonic antigen and prostate-specific antigen blood levels.

The patient was treated with high-dose (1000 mg per day) methylprednisolone followed by a tapering dose orally, in combination with methotrexate 15 mg a week, and strong topical steroids (Elocom) for skin lesions. One month later, the patient's cutaneous lesions were improved, and muscle enzymes were normal despite persistent weakness. Topical steroids were then replaced by topical tacrolimus 0.1% (Protopic). At follow-up 7 months out, he is still clinically improving (figure 1E,F), and oral steroids were stopped.

Association between DM and cancer is well established<sup>1</sup> and is correlated with the patient's immunological profile. Anti-TIF1- $\gamma$  is strongly correlated with prevalence of cancer in adult patients.<sup>2</sup> According to Schiffmann *et al*,<sup>3</sup> 42%–100% of patients positive for anti-TIF1- $\gamma$  had cancer, and anti-TIF1- $\gamma$  was detected



**Figure 2** (A) Histological analysis showing interface dermatitis with discrete and focal vacuolar modification of basal layer, atrophy of epidermis, oedema of dermis with mild interstitial inflammatory infiltrate, and rare eosinophils. (B). Alcian blue staining puts in evidence mucine accumulation in dermis.



© BMJ Publishing Group Limited 2018. No commercial re-use. See rights and permissions. Published by BMJ.

**To cite:** De Greef A, Marot L, Yildiz H, *et al*. *BMJ Case Rep* Published Online First: [please include Day Month Year]. doi:10.1136/bcr-2018-227574

## Images in...

in 22%–100% of cancer-associated DM. The most encountered DM-related cancers are ovaries, lungs, pancreas, stomach and colorectal. Haematological malignancies are less frequent. Risk for cancer is particularly increased within the 5 years after diagnosis.<sup>1</sup>

Thus, screening for cancer is an essential step when making a diagnosis of DM, especially in those with anti-TIF1- $\gamma$  antibodies. We did not find any cancer in our patient but according to the literature, it is important to maintain a close clinical follow-up and to reassess for cancer if symptoms of DM relapse.

## Learning points

- Screening for cancer is essential when making a diagnosis of dermatomyositis (DM), especially in those with anti-transcription intermediary factor 1 gamma antibodies.
- It is important to maintain a close clinical follow-up and to check for cancer if symptoms of DM relapse.

**Contributors** All authors contributed to the management of the patient. ADG contributed as the first author for the manuscript. HY and MB helped in the writing of the paper. LM helped in the interpretation of the cutaneous biopsies. All authors have read the manuscript and have confirmed that there is no conflict of interest.

**Funding** The authors have not declared a specific grant for this research from any funding agency in the public, commercial or not-for-profit sectors.

**Competing interests** None declared.

**Patient consent** Obtained.

**Provenance and peer review** Not commissioned; externally peer reviewed.

## REFERENCES

- 1 Hill CL, Zhang Y, Sigurgeirsson B, *et al.* Frequency of specific cancer types in dermatomyositis and polymyositis: a population-based study. *Lancet* 2001;357:96–100.
- 2 Thompson C, Piguat V, Choy E. The pathogenesis of dermatomyositis. *Br J Dermatol* 2017;357.
- 3 Schiffmann ML, Warneke VS, Ehrchen J. Amyopathic dermatomyositis with anti-TIF1 gamma antibodies. *J Dtsch Dermatol Ges* 2018;16:76–8.

Copyright 2018 BMJ Publishing Group. All rights reserved. For permission to reuse any of this content visit <http://group.bmj.com/group/rights-licensing/permissions>.  
BMJ Case Report Fellows may re-use this article for personal use and teaching without any further permission.

Become a Fellow of BMJ Case Reports today and you can:

- Submit as many cases as you like
- Enjoy fast sympathetic peer review and rapid publication of accepted articles
- Access all the published articles
- Re-use any of the published material for personal use and teaching without further permission

For information on Institutional Fellowships contact [consortiasales@bmjgroup.com](mailto:consortiasales@bmjgroup.com)

Visit [casereports.bmj.com](http://casereports.bmj.com) for more articles like this and to become a Fellow